



## Three Dimensional corrective osteotomy of cubitus varus by modified step cut osteotomy of supra condylar humerus

<sup>1</sup>Mohammad Abd El Aziz Ghieth MD, <sup>2</sup>Mohamed A. Sebaai MD, and <sup>3</sup>Mohamed I Kotb MD

<sup>1</sup>Ass. Professor of Orthopedic Surgery – Zagazig University

<sup>2</sup>Ass. Professor of Orthopedic Surgery – Zagazig University

<sup>3</sup>Lecturer of Orthopedic Surgery – Zagazig University

### Abstract

**Objective:** This study Outlines the technique and evaluates the functional outcome of modified step cut 3 D osteotomy for pediatric post traumatic cubitus varus deformity avoiding drawbacks of biplaner osteotomy like residual deformity, lateral prominence, loss of fixation and ulnar nerve palsies.

**Patients and methods:** 24 cases (18 boys and 6 girls) suffered from post traumatic cubitus varus deformity due to mal-united supracondylar fracture humerus. Age ranged from 3 to 13 years old (mean 5 years old). Mean management time was 3.3 years (1.5–6 years) after the injury using a modified step-cut 3 D osteotomy. The average follow-up period was 2 years (1–3.5 years). Objective assessment included measurement of preoperative and postoperative lateral prominence index, carrying angle and range of elbow motion. Results were graded excellent, good or poor according to the Oppenheim criteria.

**Results:** There were 18 excellent, 5 good and 1 poor result. A residual varus of 5° was seen in the single patient with poor result. None of the patients showed a prominent lateral humeral condyle or formation of hypertrophic scar.

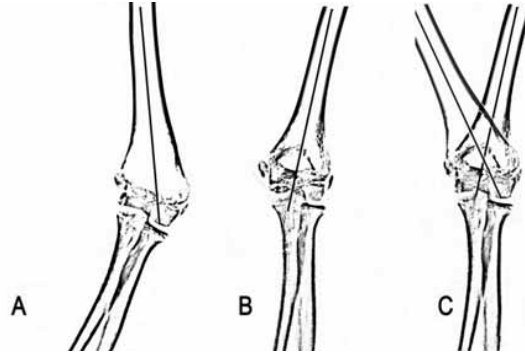
**Conclusion:** A modified step-cut 3 D osteotomy is a safe and simple osteotomy which prevents lateral prominence and provides excellent outcomes in most of the patients. The modified step-cut osteotomy procedure, was superior to the conventional lateral closing wedge osteotomy regarding the lateral humeral condyle prominence, less scaring and better cosmeses.

### INTRODUCTION:

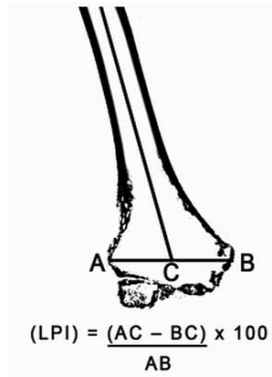
Pediatric posttraumatic cubitus varus is a major cosmetic concern for parents , despite warnings about possible complications , they are still opt for surgical correction.(1) correction should therefore be devoid of major complications and produces consistent results.(2) Various osteotomies have were described for correction namely, lateral closing wedge osteotomy , Penta lateral osteotomy, medial opening wedge osteotomy with bone graft, oblique osteotomy and step cut osteotomy, held with screws and wires.(3) Complications include the possibility of loss of correction, infection, loss of fixation, stiffness, iatrogenic nerve palsy, brachial artery injury or aneurysm and lateral condyle prominence (“Z” deformity).(4) Rotations usually do not produce deformity in the coronal plane.(5) Correction of hyperextension of the distal fragment is necessary for correcting the range of movements of the elbow.(6) Loss of reduction occurs in older children so rigid fixation by plating was required .(4) poor cosmetic appearance due to bony prominence of the lateral condylar region may occur. (7) The cause of prominence is inherent in the design of the osteotomy. Excision of the wedge in a lateral closing wedge osteotomy leaves two fragments of unequal width. Hinging on the medial cortex while closing the osteotomy effectively shifts the distal fragments laterally. Since the axis of the forearm is shifted laterally in

### Three Dimensional corrective osteotomy of cubitus varus by modified step cut osteotomy of supra condylar humerus

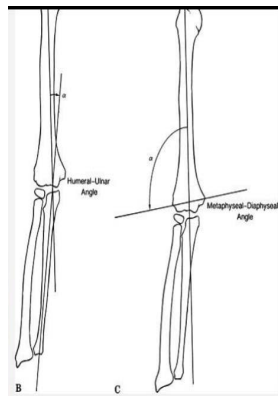
comparison with the axis of the humerus, a Z deformity develops which is usually very obvious in patients where large angular corrections are needed.(8) The advantage of the 3 D corrective osteotomy is that as the lateral base of the closed the lateral edge of the triangle is medially translated and fits into the proximal apex of the triangle so prevents a Z deformity.(8)



**Fig. 1.** — (A) The radiograph of the cubitus varus side is first traced. (B) The reversed radiograph of the unaffected forearm. (C) The affected side is superimposed over the unaffected side, and the angle between the central axes of both the affected and the normal side is the angle of correction.(9)

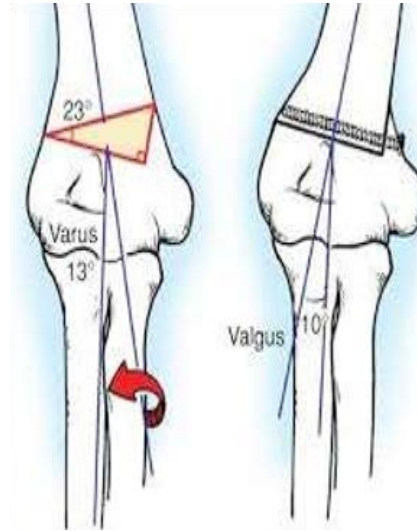


**Fig. 2.** — The lateral prominence index  
 $(LPI) = (AC - BC) \times 100 / AB$ .(9)



**Three Dimensional corrective osteotomy of cubitus varus by modified step cut osteotomy of supra condylar humerus**

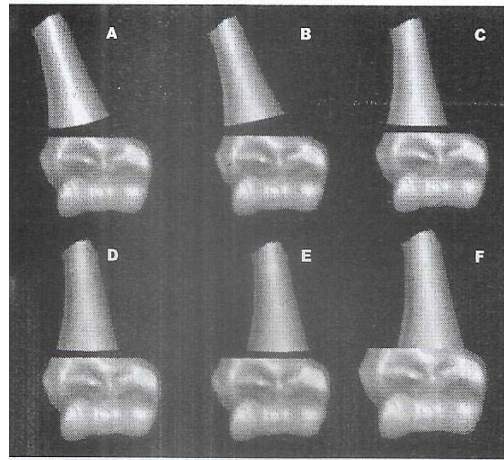
---



**Fig 4 :** ( Oppenheim ) Humero – Ulnar Angle decreased most accurate.(10)

**Fig 5 :** 3 D corrective osteomy of cubitus varus by step cut osteomy of supra condylar humerous.(8)

The preoperative planning is usually made by using two radiographs, acquired at an anteroposterior and lateral views. The main problem with this 2D-approach relies on the fact that the deformity is three dimensional, which makes it very hard to fully correct the bone malformation with information from only two different angles. since it combined the usual radiographs with a 3D model of the distal portion of the humerus. So it is possible to determine the corrective angles necessary for the planning of the osteotomy, this software can simulate surgical approach and give a 3D representation of the postoperative humerus.



**Figure 7 :** A B C D E F Steps of modified 3 D corrective osteotomy and medial translation performed using the simulation of the osteotomy until the final postoperative result is achieved: (A) Correspond the bone after performing the intersect, (B) Forming applying the lateral cut angle, (C) Doing the cutting angle, (D) The bone after rotating it according with the internal rotation of the distal deformity, (E) Corresponds to the bone after the translation is applied, and finally (F) is the final appearance of the bone, with distal and proximal parts joined together.(10)

## Three Dimensional corrective osteotomy of cubitus varus by modified step cut osteotomy of supra condylar humerus

---

### PATIENTS AND METHODS: PROP PLANNING THEN SURGICAL TECHNIQUE

Preoperative clinical assessment included measurement of the carrying angle in full extension was calculated on both sides in all patients clinically using a goniometer. The preoperative range of motion of the affected limb was measured using the goniometer must be near normal range and the status of the limb and complications like cosmetic issues, pain, instability, neurovascular issues and loss of motor power were assessed.

Anterior and lateral radiographs of the affected extremity and unaffected side were taken with elbow in full extension and forearm in full supination. Carrying angle (Humerus-Elbow-Wrist angle) was calculated on both sides and the angle of correction was estimated. Humeral-ulnar wrist angle (Oppenheim's angle) (11) has been considered as the most accurate representation of the carrying angle of the elbow, was selected as the index to measure the correction achieved. The lateral prominence index (LPI) was calculated (using the method described by Wong et al. (12) on the affected side as the difference between the measured medial and lateral widths of the bone from the longitudinal midhumeral axis and was expressed as a percentage of the total width of the distal humerus. CT and 3 D CT radiographs of the distal humerus of both upper limbs and assembly of 3 planner wedge corrective osteotomy were planned as template.

A template of the distal humerus with its deformity is obtained on a plain sheet of paper and the Humeral-Ulnar-Wrist angle is measured. The valgus angle on the normal elbow is also measured and the difference between the two carrying angles is measured. Patients in whom the difference in the Humerus-Elbow-Wrist angle between the affected and contra-lateral limbs was at least 20° and the parents wanted correction of the deformity were managed by supracondylar humerus osteotomy. All the patients, after an informed consent, were operated by a modified step-cut osteotomy. Postoperative radiographs were also taken in both AP and lateral views and CT, 3 DCT of the corrected elbow.

Surgical steps: A straight line on the distal humerus around 1.5 to 2 cm proximal to the olecranon fossa perpendicular to the lateral supracondylar ridge (that is mostly a straight line). Another is drawn of the same length at the desired angle of correction (ipsilateral varus angle + normal carrying angle).

The wedge of bone to be excised is thus planned and the alignment after this step-cut osteotomy assessed. Piece of bone from the proximal fragment is trimmed in order to maintain alignment and to avoid any lateral prominence (due to the resultant translation) is oriented preoperatively.

The lateral cortex of the proximal fragment usually required some trimming for close approximation with the spike on the distal fragment. The distal fragment was translated laterally for reduction with the proximal fragment, the reduction was provisionally fixed by Kirschner wires and assessed under C-arm. If the radiological and gross examinations showed an insufficient correction, an additional correction was obtained by further osteotomy and moving the apex medially; any overcorrection was adjusted by moving the apex laterally. After 3 D correction in coronal, sagittal and horizontal planes the reduction was rigidly fixed. Postoperatively, a posterior long arm slab applied in all the patients. This was removed after 4 weeks and controlled elbow mobilization started.

Most patients were followed up at two weeks, six weeks, 12 weeks, six months, one year and, thereafter yearly, for a maximum of 3.5 years after the surgery. The average follow-up period was 2 years (1–3.5 years). Objective clinical and radiological assessment included measurement of carrying angle, range of elbow motion, lateral prominence index, hypertrophied scar, instabilities, nerve examination.

Results were evaluated on base of Oppenheim et al. (13) as excellent, good and poor.

## Three Dimensional corrective osteotomy of cubitus varus by modified step cut osteotomy of supra condylar humerus

### RESULTS

The details regarding the general profile of the patients, preoperative range of motion, mechanism of initial injury and the treatment following the initial injury have been tabulated and compared the preoperative and postoperative results in the patients. There were no cases with preoperative nerve palsies, instabilities, local pain or limited range of motion other than the deformity in our series.

Preoperative and postoperative results details of range of motion (ROM), Humerus-Elbow-Wrist (HEW) angle difference and lateral prominence index (LPI), and mentioned are the results on the basis of Oppenheim's criteria utilized.

The mean preoperative range of motion was about  $130^{\circ}$  (range  $120-140^{\circ}$ ), while the mean range of motion at the time of the last follow-up was about  $122.5$  (range  $120-135^{\circ}$ ). This difference was not statistically significant ( $P = 0.34$ ). There were 4 children (16.6%) with a postoperative decrease in the range of motion of less than or equal to  $5^{\circ}$ , while the decrease in the range of motion was between  $5$  and  $10^{\circ}$  in 3 patients (12.5%) show no significant difference ( $P = 0.32$ ). No patient had a decrease in motion of more than  $10^{\circ}$ .

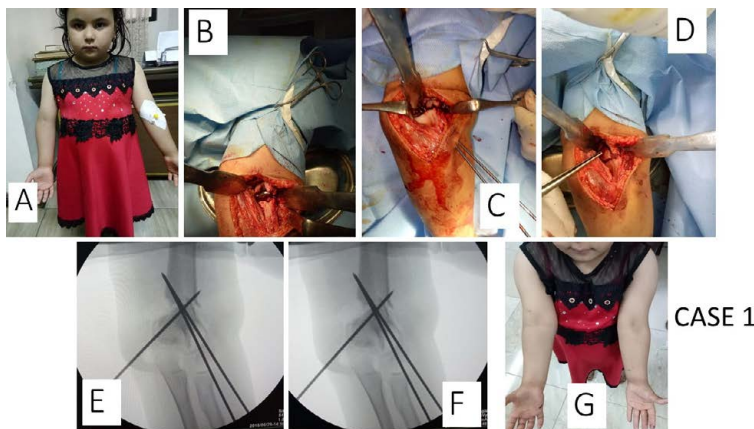
The mean preoperative difference in carrying angle (HEW Angle) between the two limbs was  $26.6$  (range  $25-35^{\circ}$ ) while postoperatively and at follow-up, the difference was  $2^{\circ}$  ( $-2$  to  $5^{\circ}$ ). There was no loss of correction once achieved, observed in any of our patients following modified step-cut osteotomy. Most of the patients had a correction of HEW angle to within  $5^{\circ}$  of the normal arm show no significant difference ( $P = 0.43$ ).

The preoperative LPI averaged  $0.08\%$  (range  $-7\%$  to  $6.5\%$ ) in our study. The mean postoperative LPI was  $-0.85\%$  (range  $-9\%$  to  $5\%$ ). A negative LPI value indicates a greater medial prominence at the elbow. Compared with the preoperative values, the LPI actually decreased after the surgery in all our cases showing significant difference ( $P = 0.04$ ).

On the basis of the Oppenheim's criteria, there were 18 patients (75%) with excellent results, 5 patients (20.8%) with good results and one patient (4.2%) with poor result. None of the patients had wound infection, nerve palsies, instabilities or any significant postoperative complications. All of them demonstrated good solid union at 12 weeks.

The forearm supination-pronation were not changed postoperatively. Compared with the normal side, the average preoperative internal rotation was  $20^{\circ}$  (range,  $0^{\circ}-30^{\circ}$ ), which was corrected to  $5^{\circ}$  (range,  $0^{\circ}-5^{\circ}$ ) postoperatively. Before the operation, 16 patients had more than  $20^{\circ}$  internal rotation, but after the operation, no patient had more than  $5^{\circ}$  internal rotation deformity.

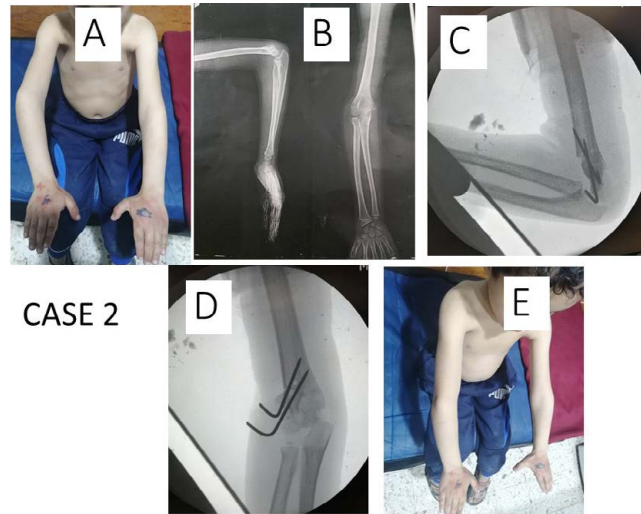Case presentation: CASE 1, CASE 2





## Three Dimensional corrective osteotomy of cubitus varus by modified step cut osteotomy of supra condylar humerus

---



*CASE 1: female 5 years old with posttraumatic cubitus varus: A) preoperative photo with rt cubitus varus, B, C, D) Intraoperative photos of surgical approach, E& F) intraoperative radiology after osteotomy fixation, G) postoperative photo with corrected deformity and full extension.*

*CASE 2: male 6 years old with posttraumatic cubitus varus: A) preoperative photo with right cubitus varus, B) preoperative x-ray, C&D) Intraoperative photos of surgical approach, E) postoperative photo with corrected deformity and full extension.*

### DISCUSSION

Ali Mourady (2013) Results were comparable to the published results of the classical lateral closing wedge osteotomy in terms of elbow motion and correction of deformity. There were 8 excellent, 5 good and 1 poor results. A residual varus of more than  $10^{\circ}$  was seen in the single patient with poor result. None of the patients showed a prominent lateral humeral condyle or formation of hypertrophic scar. (15)

Srivastva (2008) Results were Average preoperative varus was measured 20.1 degrees (range 16-25), immediate postoperative and 12<sup>th</sup> week postoperative valgus was angle 14.4 degrees (range 12-17 degrees). The radiological valgus obtained on the operated side was near equal to valgus of normal side with a mean variation of  $\pm 1.91$  degrees (range - 2 in case no. 20 to + 4 degrees in case no. 10 at 12-week follow-up. Cosmetically all were satisfied with the results outcome. There had been no neurovascular complication, unsightly scar or any residual deformity. Stable fixation had led most of the cases to achieve  $>170$  degree of supination- pronation,  $<5-10$  degrees of restriction of flexion-extension in the majority of the cases. Most of cases were able to regain their pre-injury functional status in the ninth week postoperatively with excellent cosmetic correction.(14)

In Chung (2003) Results, the average humerus-elbow-wrist angle improved from  $-26^{\circ}$  to  $11^{\circ}$ . The mean lateral prominence index did not differ after correction of deformity when compared with the normal side. By using good rehabilitation protocol, all patients regained preoperative arcs of elbow motion in a mean of 2.5 months (range, 1.50–3.50 months) postoperatively, and the mean bony union time was 1.65 months. According to the criteria of Openheim et al., the results were 11 excellent and two good results.(4)

Sulaiman Sath ( 2016 ) used lateral closed wedge osteotomy with plating an recommended that it is safe and effective method of correction of cubitus varus in adolescents and adults. Their results of total 12 cases (7 males and 5 females) with a mean age of 19.41 years. Most cases were right handed forming 8 of the 12 cases

## Three Dimensional corrective osteotomy of cubitus varus by modified step cut osteotomy of supra condylar humerus

---

(66.66%). Mean carrying angle on the normal side was  $9.16^{\circ}$  while mean varus deformity of the affected side was  $17.16^{\circ}$ . Follow-up period ranged from 6 to 24 months. Postoperative valgus obtained was with a mean of  $8.66^{\circ}$  which is close to the mean of carrying angle on normal side. Mean range of motion preoperatively was  $134.16^{\circ}$  while postoperatively it was  $132.5^{\circ}$ . There was a hyperextension of  $10^{\circ}$  in one patient who continued to have the same in the postoperatively. One patient had loss of terminal  $5^{\circ}$ - $10^{\circ}$  of extension. Mean time for clinical union was 11.75 weeks. Lateral condylar prominence index changed from a mean of 5.23 (ranging from 2.5-7.8) to -10.95 (ranging from -5 to -18.4). Good to excellent outcome were observed in all patients. (16)

Srijay Sashaank. (2017) studied the radiological and functional outcomes following corrective osteotomy in cubitus varus deformities and to assess the outcomes of commonly used osteotomies. Prospective study done between 2014-2017. Total number of patients in the study were 9. Age group of the patients under our study were 3-15 years, mean age being 7 years (6 Boys and 3 girls). All deformities resulted from malunion of distal humeral supracondylar fractures sustained by the patients when they were from 3 years to 15 years of age. There was a mean internal rotation deformity of 10 degrees measured by comparing the arc of rotations of the ipsilateral shoulder with the contralateral shoulder. None of the selected patients for osteotomy had a distal neurological deficit or myositis ossificans. (17)

### CONCLUSION:

The modified step-cut 3 D osteotomy is a safe and simple osteotomy which prevents lateral prominence and provides excellent outcomes in most of the patients. The modified step-cut osteotomy procedure, was superior to the conventional lateral closing wedge osteotomy regarding the lateral humeral condyle prominence, less scarring and better cosmeses.

### REFERENCES

- Bellemore MC, Barrett IR, Middleton RW, Scougall JS, Whiteway DW.** : Supracondylar osteotomy of the humerus for correction of cubitus varus. *J Bone Joint Surg Br.* 1984;66:566–572. [PubMed] [Google Scholar]
- Butt MF, Dhar SA, Farooq M, Kawoosa AA, Mir MR.** *Lateral invaginating peg (LIP)* : osteotomy for the correction of post-traumatic cubitus varus deformity. *J Pediatr Orthop B.* 2009;18:265270. doi:10.1097/BPB.0b013e32832c2f09. [PubMed] [CrossRef][Google Scholar]
- Canale ST, ed.** : Surgical approaches. In: *Campbell's Operative Orthopaedics*. Vol 2. 11<sup>th</sup>Ed. St Louis, MO: CV Mosby; 2008:1592.
- Chung MS, Baek GH.** : Three-dimensional corrective osteotomy for cubitus varus in adults. *J Shoulder Elbow Surg.* 2003;12:472–475. doi: 10.1016/S1058-2746(03)00090-9. [PubMed] [CrossRef] [Google Scholar]
- D'Ambrosia RD.** : Supracondylar fractures of humerus: prevention of cubitus varus. *J Bone Joint Surg Am.* 1972;54:60–66. [PubMed] [Google Scholar]
- Gong HS, Chung MS, Oh JH, Cho HE, Baek GH.** : Oblique closing wedge osteotomy and lateral plating for cubitus varus in adults. *Clin Orthop Relat Res.* 2008;466:899–906. doi: 10.1007/s11999-008-0164-0. [PMC free article] [PubMed] [CrossRef] [Google Scholar]
- Graham B, Tredwell SJ, Beauchamp RD, Bell HM.** : Supracondylar osteotomy of the humerus for correction of cubitus varus. *J Pediatr Orthop.* 1990;10:228–231. [PubMed][Google Scholar]
- Dauids JR, Lamoreaux DC, Brooker RC, Tanner SL, Westberry DE.** : Translation step-cut osteotomy for the treatment of posttraumatic cubitus varus. *J Pediatr Orthop.* 2011;31:353–365. doi: 10.1097/BPO.0b013e31821723a6. [PubMed] [CrossRef] [Google Scholar].
- Wael EL- ADL** : The equal limbs lateral closing wedge osteotomy for correction of cubitus varus in children –

## Three Dimensional corrective osteotomy of cubitus varus by modified step cut osteotomy of supra condylar humerus

---

Acta Orthop., Belg, ( 2007 , 73 , 508 – 587 ).

**João Tiago Pião Martins** : Preoperative Planning Software for Corrective Osteotomy in Cubitus Varus and Valgus , Superior Técnico — Universidade de Lisboa (1ST) November 2016.

**Mann TS** . : Prognosis in supracondylar fractures. J Bone Joint Surg Br. 1963;45:516–522.[PubMed] [Google Scholar].

**Wong HK, Lee EH, Balasubramaniam P** : The lateral condylar prominence: a complication of supracondylar osteotomy for cubitus varus. J Bone Joint Surg Br. 1990;72:859–861.[PubMed] [Google Scholar].

**Kasser JR, Beaty JH** . : Supracondylar fractures of the distal humerus. In: Beaty JH, Kasser JR, editors. Rockwood and Wilkins' Fractures in Children. 5. Philadelphia, PA: Lippincott, Williams & Wilkins; 2001. pp. 577–624. [Google Scholar].

**Amit K Srivastava, DC Srivastava, and SC Gaur** : Lateral closed wedge osteotomy for cubitus varus deformity - Indian J Orthop 2008 Oct-Dec; 42(4): 466—470. doi: 10.4103/0019-5413.43397 .

**Ali Moradi MD, Ehsan Vahedi MD, and Mohammad H. Ebrahimzadeh MD** : Surgical Technique: Spike Translation: A New Modification in Step-cut Osteotomy for Cubitus Varus Deformity. Clin Orthop Relat Res v.471(5); 2013 May PMC361 3533

**Sulaiman Sath, Nissar A Shah, Maajid Shabeer Peerzada** : wedge osteotomy and plating in adolescents and adults: A case study of 12 patients Observations on the correction of cubitus varus post supracondylar fracture of humerus by lateral closed International Journal of Orthopaedics Sciences 2016; 2(1): 01-05.

**Srijay Sashaank. S , Giriraj J.K, Gopinath Menon P** : deformity Correction in Cubitus Varus-Our Experience 1051 .Journal of dental and Medical Sciences (IOSR-JDMS) : 2270-0 p-ISSN: 2279-0861.Volume 16, Issue 2 Ver. IV (February. 2017), PP /32-137

**Citation:** **Mohammad Abd El Aziz Ghieth MD, Mohamed A. Sebaai MD, and Mohamed I Kotb MD**, "Three Dimensional corrective osteotomy of cubitus varus by modified step cut osteotomy of supra condylar humerus". *American Research Journal of Orthopedics and Traumatology*. 2020; 4(1): 1-8.

**Copyright © 2020 Mohammad Abd El Aziz Ghieth MD, Mohamed A. Sebaai MD, and Mohamed I Kotb MD**, This is an open access article distributed under the Creative Commons Attribution License, which permits unrestricted use, distribution, and reproduction in any medium, provided the original work is properly cited.